

Laser therapy for soft tissue injury, wound management

Wound healing competence with RJ-LASER devices

Patient, female, age 45 years

The patient had a traffic accident on the evening of the 11th of June followed by acute care in the local hospital. The patient suffered under severe soft tissue damages on the mouth and lip nose area, a deep laceration inside the upper lip was closed by the surgeon with three stitches. Four frontal teeth were destroyed. Bone and soft tissue trauma on cheeks and face area. Joint injury on the hands and knee.

Because of the injury the patient could not move lips or open the mouth prior to laser therapy. The joints on the hands were swollen and hard to move.

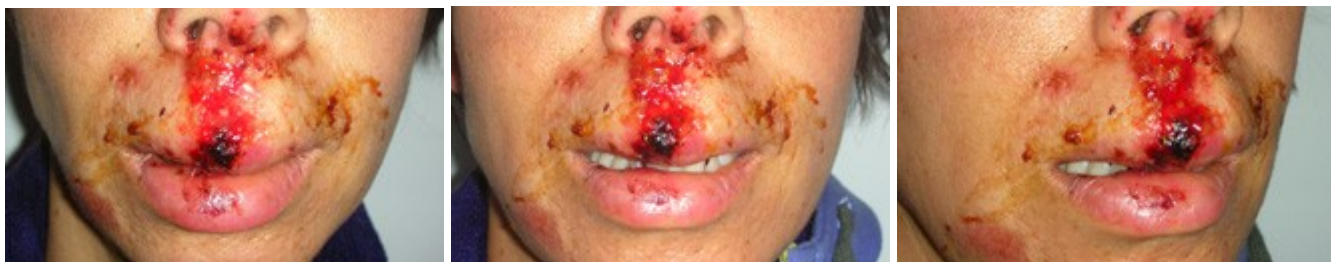It was important to reduce the risk of scars in the facial area. The laser therapy was the method of choice to perform fast and stable wound management, pain free condition and scare free tissue healing.

The patient is very thankful for this gentle and fast therapy. Pain free healing success within one week.

The therapy started in the morning after the accident.

Time	15 minutes (approx. 190 Joule) 3x daily during the first 2 days, thereafter 2x daily and the last 4 days 1x daily
Frequency	Derma program, wound acute
Power	500 mW/810 nm + 50 mW/650 nm
Device	Photonic 500 Info
Additional	No wound dressing or extra treatment
Clinic	RJ-LASER Research Department Leonhardtstr. 5, 14057 Berlin, Germany 12.-18. June 2008

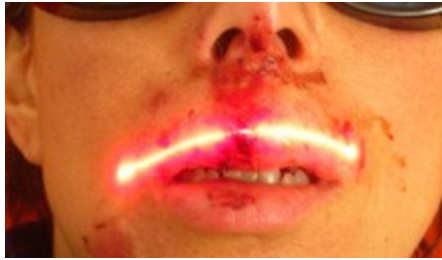This therapy was fast and successful and led to complete scar free healing



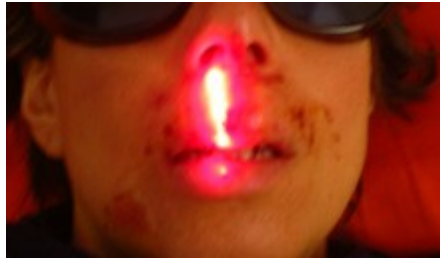Day 1: The morning after the accident, before laser therapy. **The wound was still wet without any closure, severe pain.** The lip mouth area was swollen and jaw movement obstructed.

Day 1: Immediately after the first treatment the wound started to get dry and pain was reduced. The edema began to decrease.

Day 1: After the 3rd treatment on the first day the wound was almost dry, edema reduced and scurf started to grow rapidly.



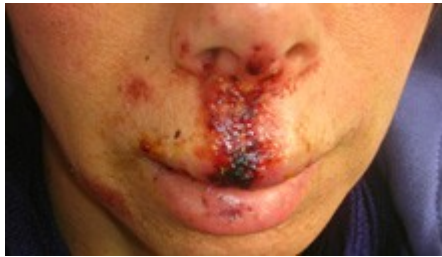Treatment of the horizontal total lip and mouth area to reduce edema and increase healing.



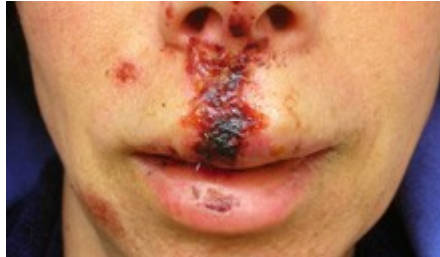Treatment of the vertical wound center to for cell stimulation to increase healing.



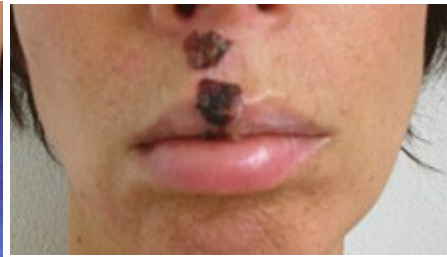Treatment of the joint injuries with pulsed circle.



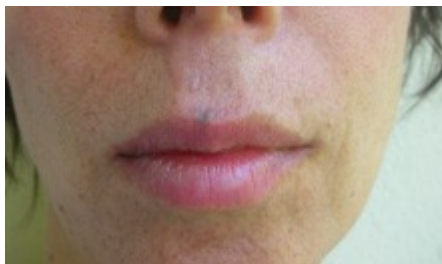Day 2: Completely covered with scurf, dry wound less edema.



Day 4: Reduced wound size, reduced edema.



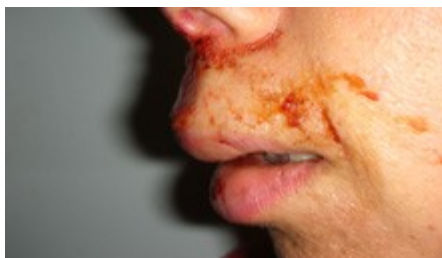Day 7: The crust already started to fall of. Beside some redness the skin was normal.



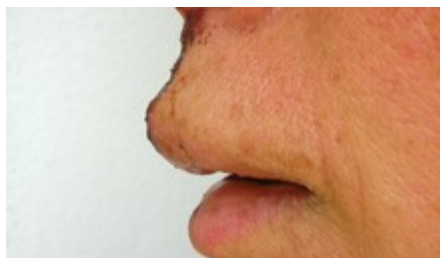
Day 9 (last two days no laser therapy): Except of a tiny spot which is still fading away, the skin and deeper tissue layers are normal in color and size and -very important- scar free.

Advantages of the RJ laser therapy:

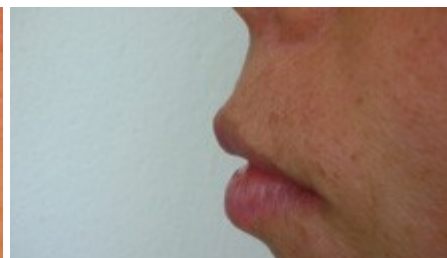
- fast, no pain, scar free tissue healing
- avoiding infections
- low cost treatment
- economical + profitable for the clinic



Day 1: Side view the morning after the accident.



Day 3-4 Side view.



Day 8: Side view, normal lip size.



The therapy was made with the



Alternative 1:



Alternative 2:

Photonic 500.

Physiolaser + multi-cluster

Polylaser trion

Single probe treatment is possible with stand, please ask for more information. RJ offers various solutions for fast and easy handling (one hand adjustment).

